



DAN LAZAR

--

FOUR LEVELS OF INVERSION FOR RUBBER DAM ISOLATION

40224 Views - May 2017

As we know from the thousands articles, in the Literature, about adhesion, isolation is a mandatory procedure. On the other hand, this step is sometimes not so easy to carry out, and we are pushed to give up quickly.

The need to work under dry conditions in the oral cavity has been recognized for many decades now, and the idea of using a rubber sheet to isolate the tooth dates more than 150 years! The use of the rubber dam was first described in 1864 in New York by a dentist, Sanford Christie Barnum, who demonstrated the advantages of isolating the tooth with a rubber sheet. Imagine that, in that period of time, there was no adhesive procedure, so the question that comes to mind is: "Why, in the first place did he choose to work with a rubber dam?"

A good isolation - what does it mean?

You will get a good isolation when you will physically separate the teeth you want to operate from the surrounding environment and keep them dry and clean during the whole procedure.

The first thing to aim for is a very good INVERSION, that means placing the rubber around the cervical area and in the sulcus, and keep it there until the end of the restorative process. In other words, we should place the rubber under the limit of our preparation. Good isolation also means:

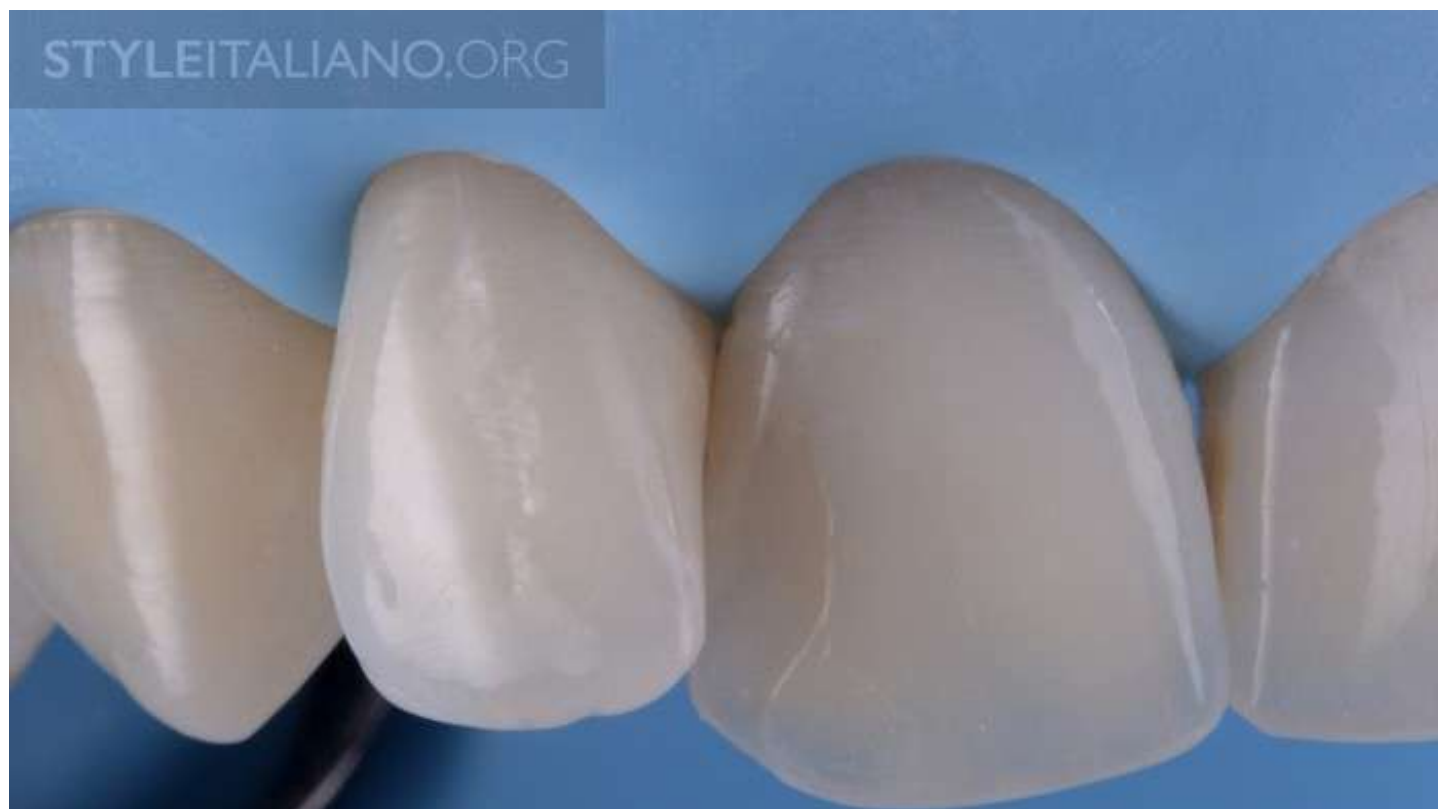Dry working field;

Having a large working field;

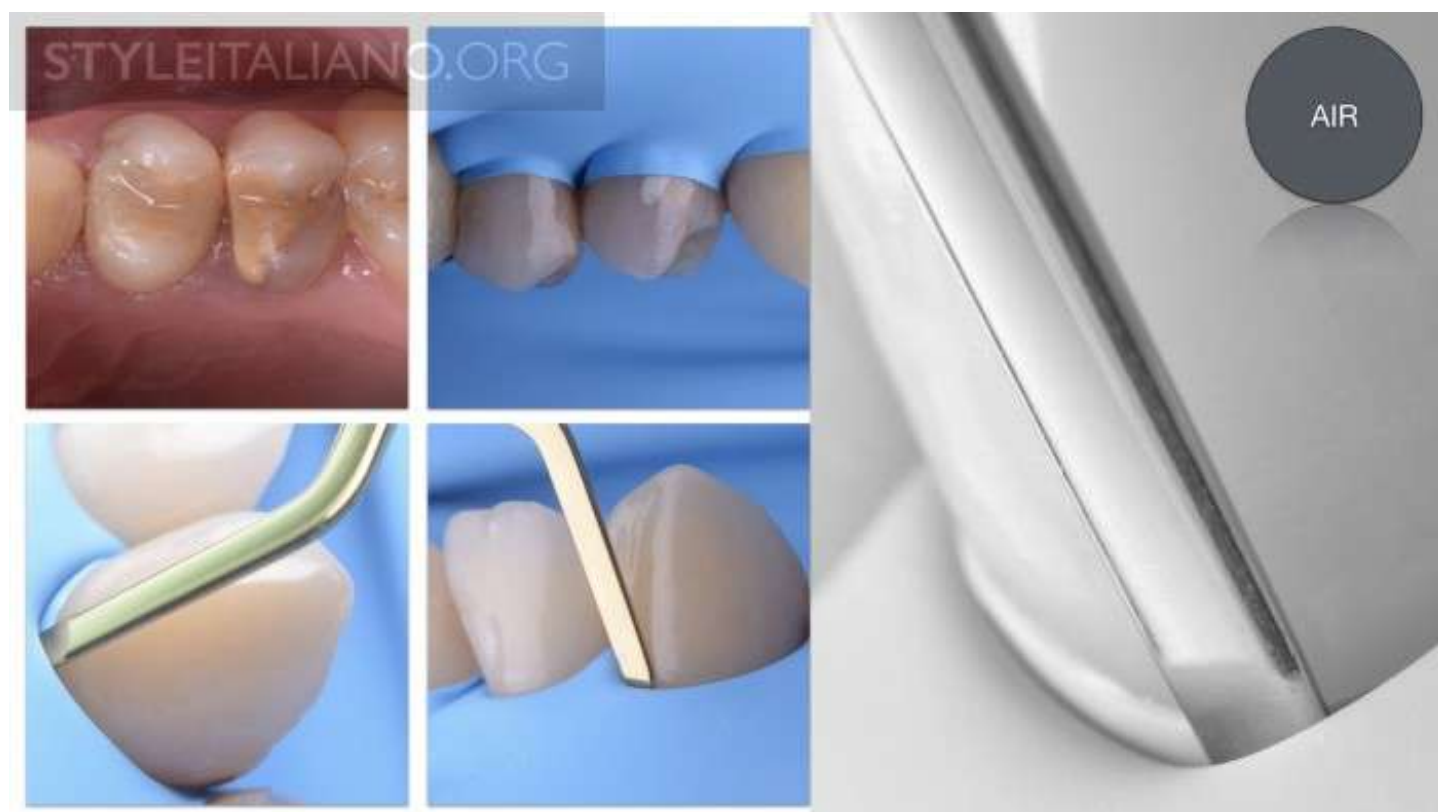Maximum tissue retraction;

Minimal interference with restorative procedures.

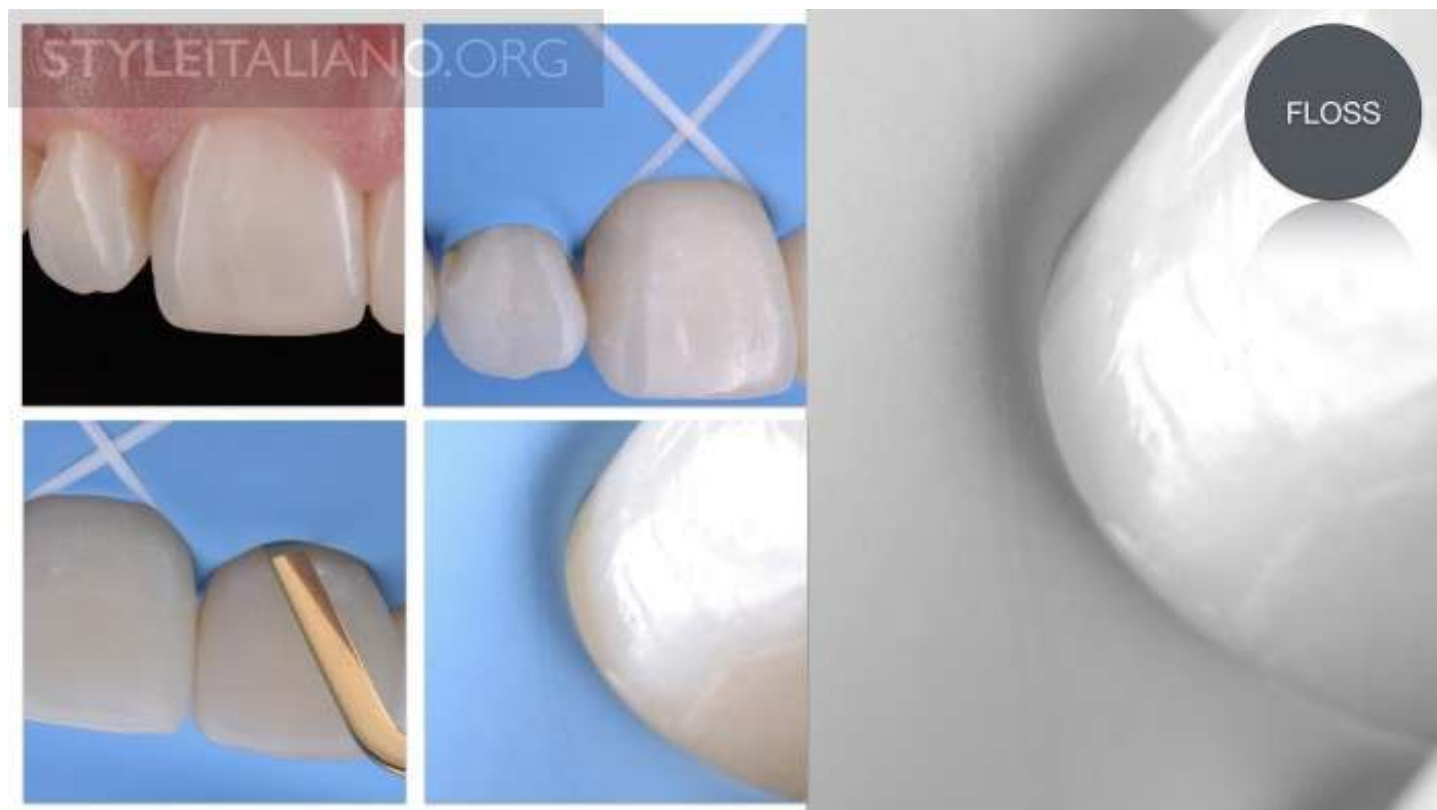In order to find new solutions for better and faster inversion, different techniques and materials were developed different.



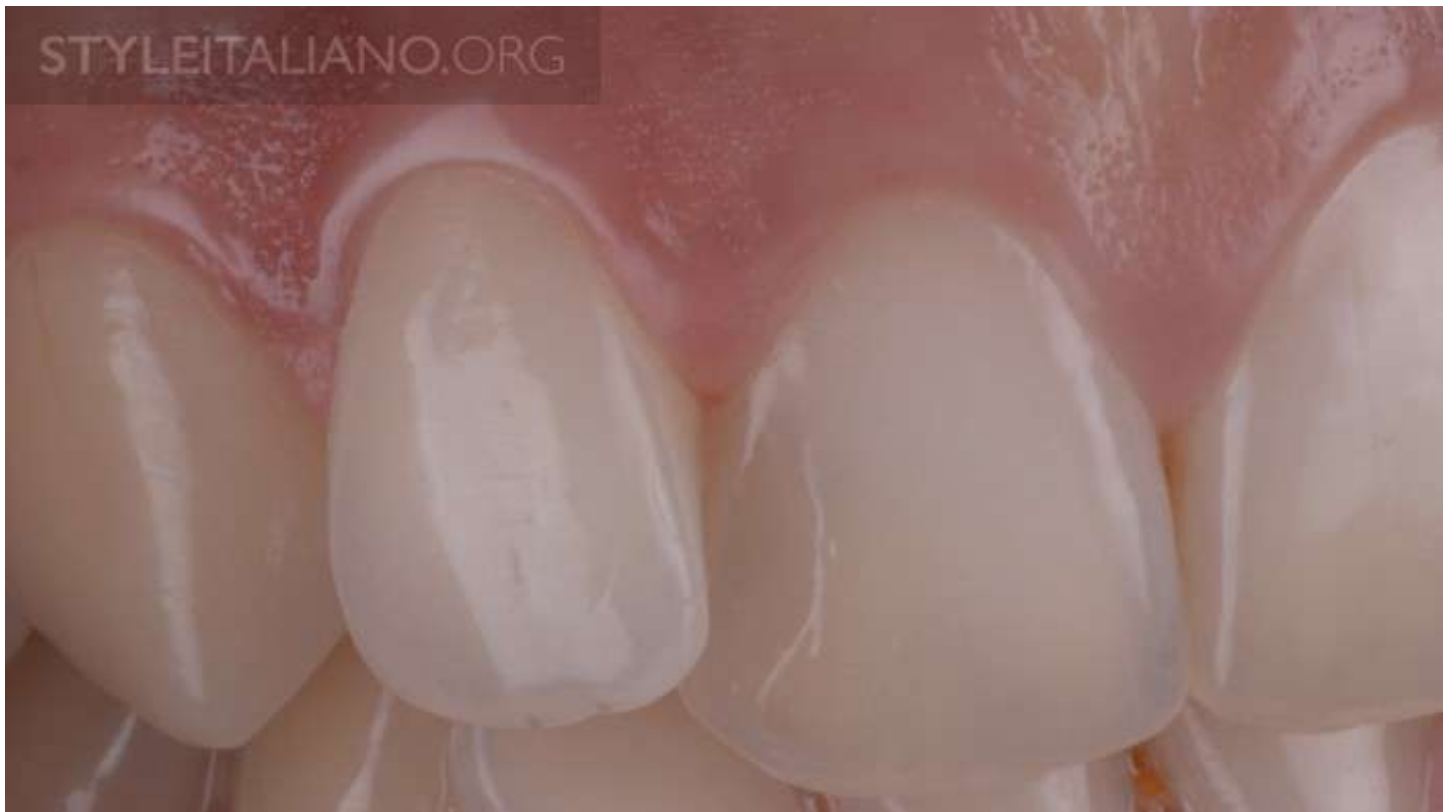Img. 1 - The main objective, speaking about isolation is to “separate” the teeth from the oral cavity, to actually keep oral fluids and surrounding tissues away. The weakest points of the rubber are, in fact, the holes that were done with the punch. After the rubber dam is in place, the first thing to do is to put the rubber under the gingival margin, into the sulcus. This process is called INVERSION: in other words, inversion is a procedure through which the operator slips the peripheral rubber of the hole around the cervical area of the tooth and into the sulcus, and keeps it still during the whole restorative procedure. A very important rule is that the rubber should sit around the cervical area passively. If the rubber is in tension, the inversion is almost impossible to get. The elastic properties of the rubber are very helpful in this process.



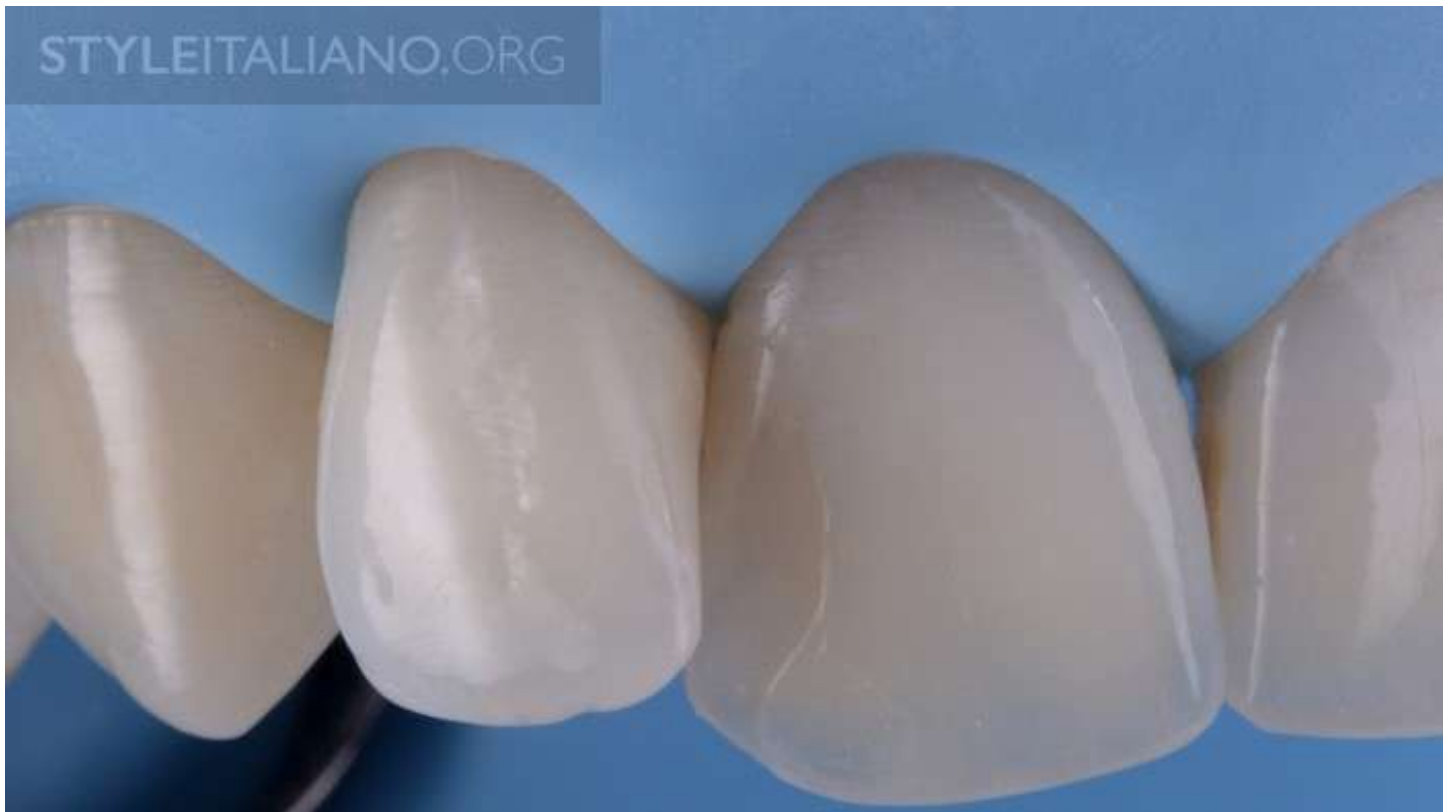Img. 2 - Level 1 - AIR INVERSION: The easiest way of getting inversion is by blowing air around the cervical area and, at the same time, delicately pushing the rubber into the sulcus with a spatula. Actually, what happens is that the rubber, in contact with a dry tooth, will not slide, so it will stay in the cervical area. This technique works very nicely when the limit of our preparation is supragingival. There are some situations, though, in which this technique doesn't work. When excess saliva is under the rubber, it is hardly manageable to dry the teeth; for this reason I recommend using some cotton rolls in the vestibule during rubber dam isolation. Another challenging situation, is when teeth are not completely erupted, and the maximum convexity is placed at the gingival area; this issue can be solved by using dental floss ligatures, or by using an additional clamp. These two solutions will be discussed later on.



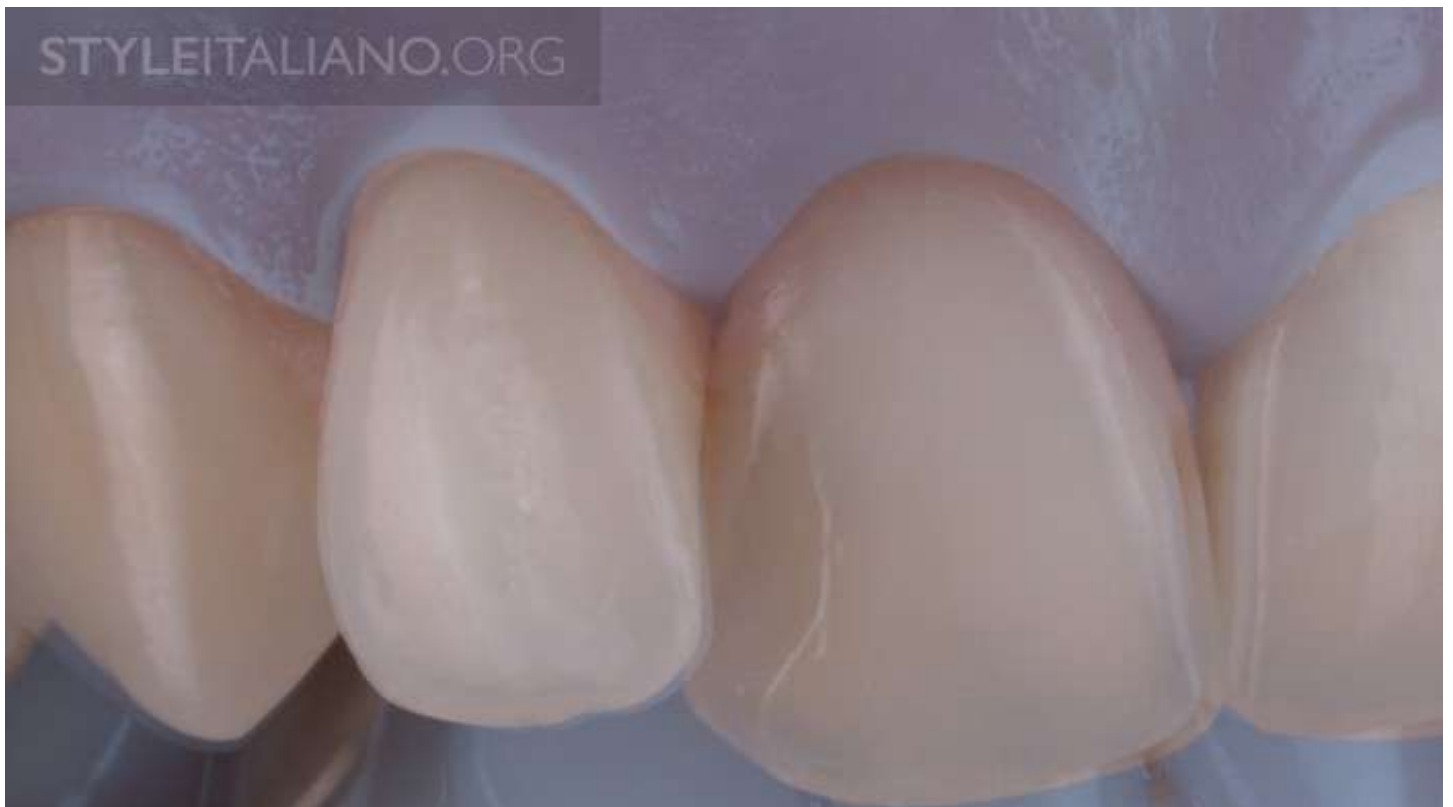Img. 3 - Level 2 - INVERSION WITH DENTAL FLOSS: There are some quite frequent cases, as previously mentioned, in which air inversion just doesn't work at all. In these cases, a strategy to invert the rubber dam in the sulcus is to use a dental floss placed around the tooth; with apical pressure and slow movements the rubber dam should roll and be inverted. The inversion should be done to all the teeth that we want to be isolated (e.g. quadrant), meaning not just around the teeth that are operated, in order to prevent surprises during our adhesive procedures, such as drops of saliva appearing in the area where the inversion was not properly made.



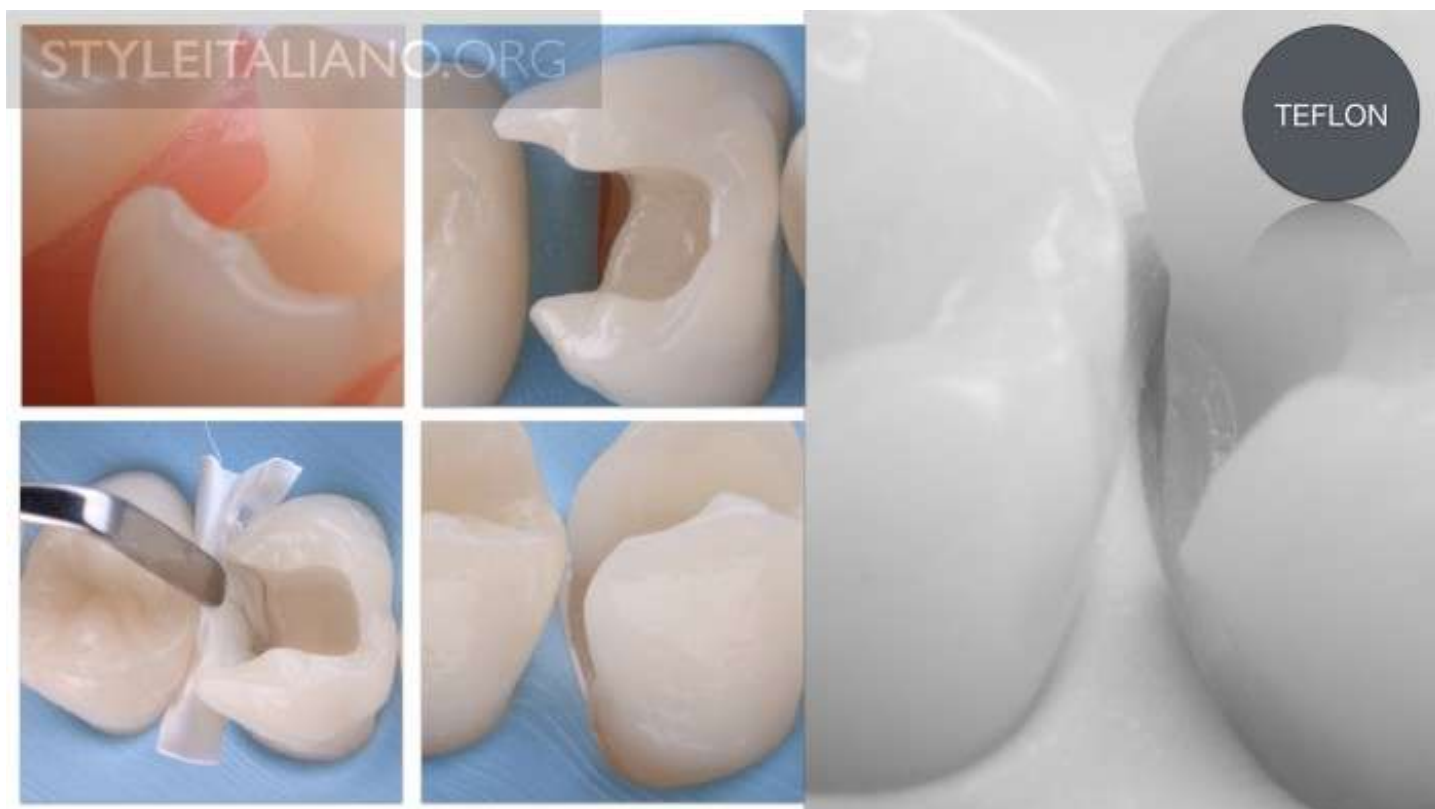
Img. 4 - Level 3 - INVERSION WITH KNOT LIGATURES: This technique has, in my opinion, a big advantage. I've very often been using this technique, especially when I have a class 2 or 3 cavity, or when I isolate to cement a ceramic restoration with supragingival margins. This technique provides two main advantages: one is that the floss pushes the rubber deep in the sulcus, close to the epithelial insertion, and second, the floss tightens around the tooth and holds the rubber dam in place during the restorative procedure. This option of isolation can only work if the destruction limit doesn't affect the epithelial insertion. Since the rubber and floss are materials that have elastic properties, they won't go more subgingivally than the epithelial insertion. Each time we have a situation in which the lesion is deeper than the epithelial insertion, we should change our strategy. In the next paragraph some a technique will be described, that can help you to isolate in very difficult cases.



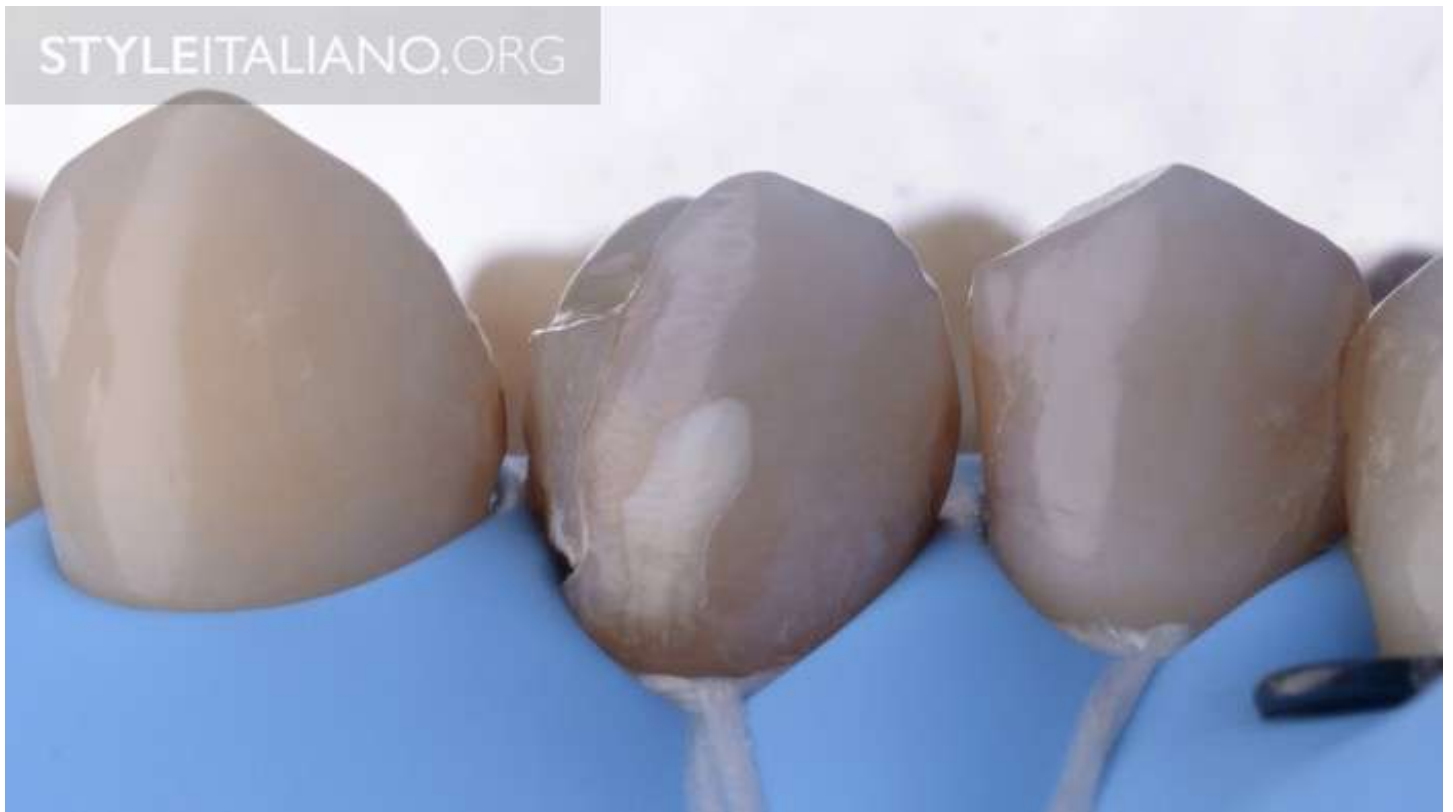Img. 5 - This picture shows inversion with knot ligatures.



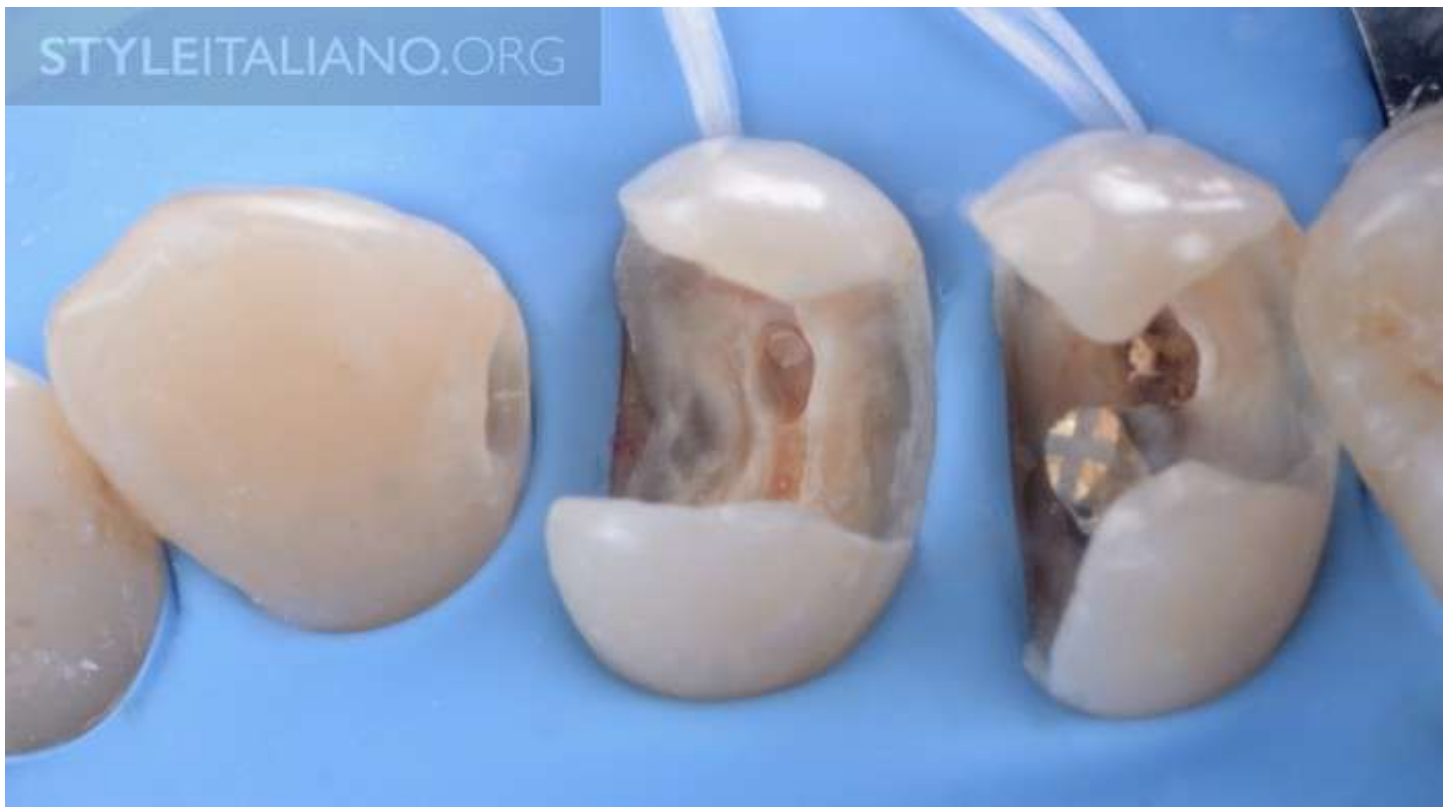Img. 6 - With this technique, the rubber pushes the gingival tissue interproximally, up to some millimeters in some cases, which helps the dentist to have a better view.



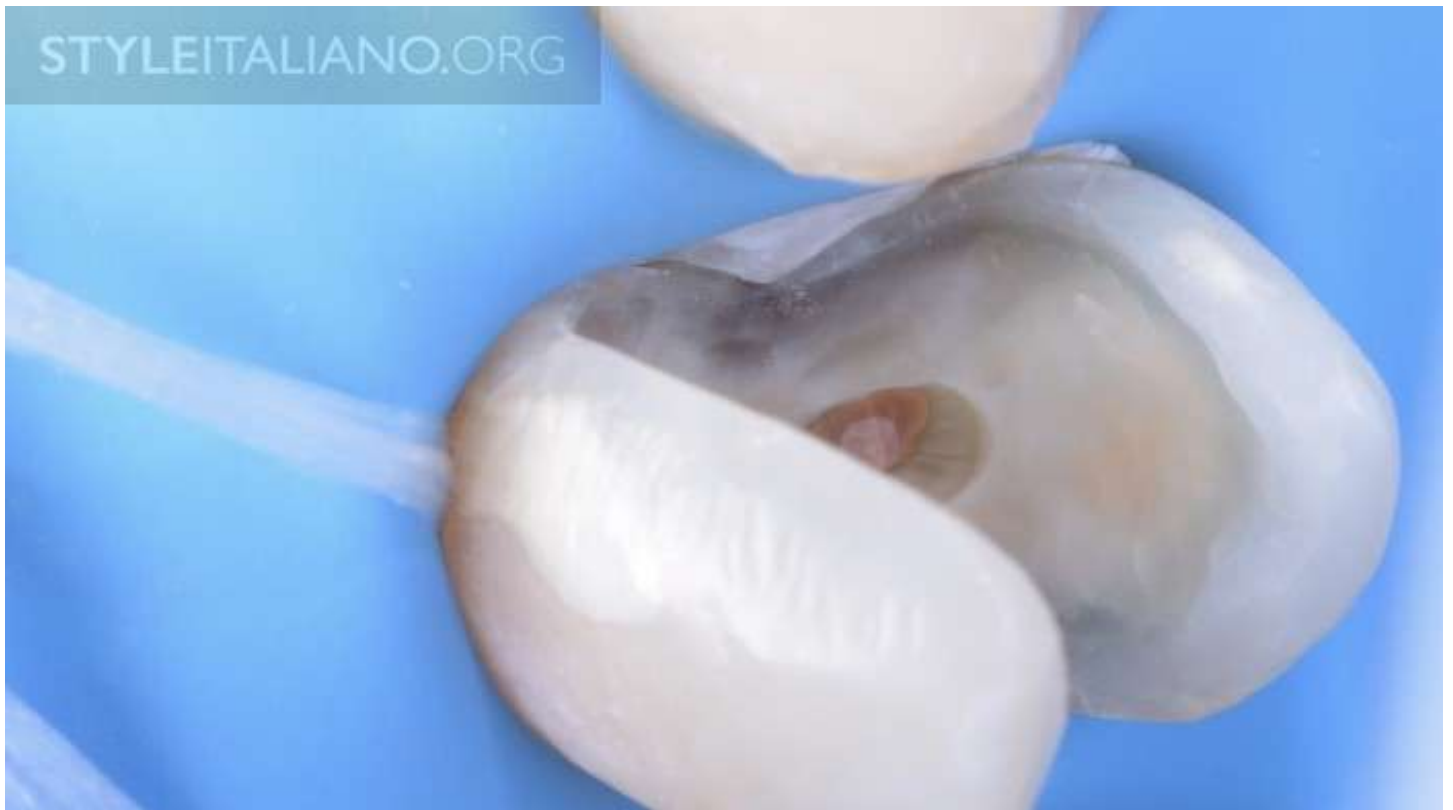Img. 7 - Level 4 - INVERSION USING TEFLON TAPE: When we use this technique for inversion, it means that we have some problems with the isolation. By using teflon tape, we can place the rubber deep subgingivally in the sulcus and place it under the limit of our preparation. Teflon is more often used to push the rubber in a vertical direction in some areas of the tooth. In class 2 cavities, for example, the destruction of the cavity is close to the epithelial insertion, so inversion with dental floss is not possible. Why is that? For me, it was very clear when I imagined the epithelial insertion as a red limit around the tooth; this RED LINE we are not allowed to destroy during the inversion procedure. Now, that cervical limit of the cavity or preparation often touches or goes under this red line. In these cases, the rubber dam will stay on the red line and, in that particular area will not be able to be inverted by air, dental floss or knot ligatures. Using a piece of teflon tape pushed with a wet spatula allows a deeper positioning of the rubber dam, under the limits of the preparation. For sure that this is not an easy procedure, and sometimes you will need your dental assistant help. Teflon is a material that has plastic properties : when pushed with a spatula, it sticks so that it might come out when the spatula is removed; for this reason it is advisable to use another instrument (e.g. a tweezer, spatula or other) to hold against the removal of teflon. For those dentists who don't like this technique, as it can take some extra time, some other techniques can work. Another way to isolate in deep subgingival cavities is to remove a part from the gingiva with a surgical blade, laser or other cutting instrument; after gingival removal, the blood should be stopped in order to simplify the isolation procedures. I prefer to use an electric surgical blade or laser, because the control of the bleeding is very good. The level of the gingiva after the gingivoplasty, should be brought deeper than the level of the preparation and the level of the epithelial insertion of the buccal and oral region. With this new situation the inversion is easier and sometimes can work by using dental floss or ligatures.



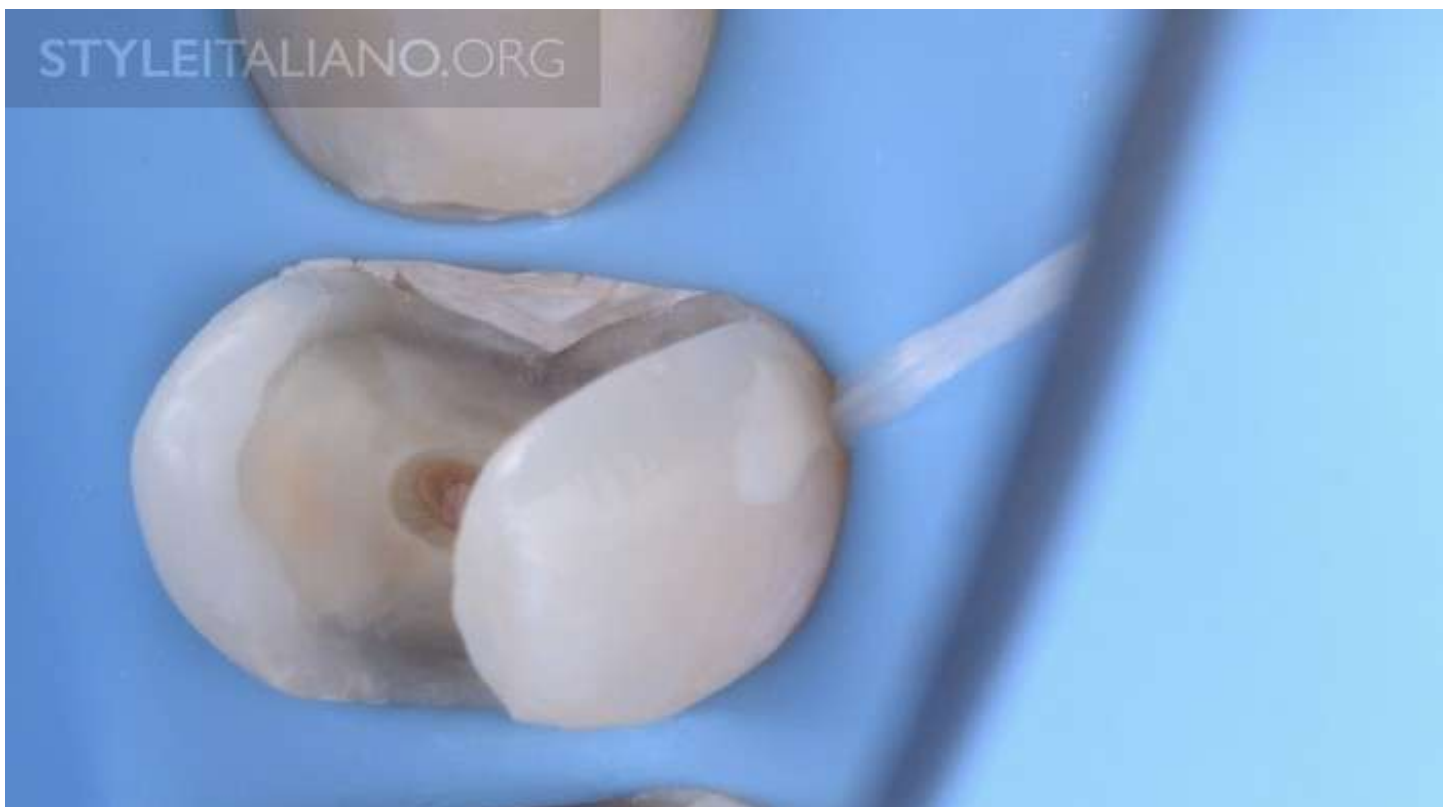Img. 8 - Clinical case with inversion with knot ligatures



Img. 9 - After removal of the old composite the proximal areas were not isolated.



Img. 10 - A teflon tape was used to isolate the proximal area.



Img. 11 - At this time we are ready to do the restoration.

Now we have all the tools and solutions to isolate in almost all the most challenging situations. If, still, we can't isolate, we could then ask ourselves if that tooth has a good prognosis over time. I use the following rule a lot - "If I can't isolate, that tooth is not restorable in that condition", that leads me to clinical choices as a crown lengthening or doubts about the prognosis of that tooth.

Visit: <http://styleitaliano.org/four-levels-of-inversion-for-rubber-dam-isolation>